



Comparison of Human Cortical Surface Reconstructions from Magnetic Resonance Imaging Data



Aaron D. Kline, Deborah A. Smith, Monica K. Hurdal

Department of Mathematics, Florida State University, Tallahassee, Florida, U.S.A. 32306-4510
International Neuroimaging Consortium (INC)

Introduction

Increasingly, brain cartographic methods are being implemented in attempts to create cortical surface reconstructions that are useful and accurate. Aesthetically pleasing images of the human cortical surface have been rendered, but beyond visual appeal, these reconstructions need to represent the true surface. Creating high quality surfaces is a nontrivial objective, for they must be topologically correct and accurately represent cerebral anatomy. The purpose of our study is to examine the biases, differences, and similarities between the surface reconstructions of INCsurf (INC)[1], BrainVISA (BV)[2], and FreeSurfer (FS)[3].

Methods

High resolution 1.5T, T1-weighted MRI brain scans (0.86mm x 0.86mm x 1.00mm) from 11 subjects (mean age: 26, 5 females, 6 males) obtained in a static force experiment[4] were used to compare surface reconstructions from three methods. A typical pipeline performs intensity corrections in the MRI scan, strips the skull, removes the cerebellum, bisects the cerebral hemispheres, and creates triangulated surfaces. The amount of user input involved in these processes varies from selecting a few points on an MRI to manual editing a surface.

INCsurf processes MRI data that have been intensity corrected and stripped of any non-brain regions. We intensity corrected the data with the Montreal Neurological Institute's N3 algorithm. Non-brain regions were removed by semi-automated in-house software. An isovalue, corresponding to the interface between the gray matter (GM) and the white matter (WM) is then selected by the user with the aid of an intensity histogram. The INCsurf algorithm utilizes the user selected isovalue to select voxels that are designated members of a growing region. This region is grown to create the volume contained by the GM surface, while maintaining correct topology. A surface mesh is created from the exposed voxel faces. Smoothing of the GM surface completes the processing. Moderate user input is required with INCsurf.

BrainVISA requires the software operator to identify the right and left hemisphere in addition to specifying the locations of the anterior and posterior commissures. After these points have been visually identified, the data is sent through a fully automated pipeline which processes the data to completion. Automated intensity histogram analysis and the use of "Markovian regularization" results in the binary classification of voxels. Seed growing is used to remove the cerebellum and to identify the proper location to split the two hemispheres, resulting in a Voronoi tessellation. BrainVISA creates topologically correct WM surfaces, though its GM surfaces are not always topologically correct with the version available at time of study. Very low user input is necessary to operate the BrainVISA software package.

FreeSurfer requires more user input than the other two software applications. Intensity correction and other initial processing is automated. With each hemisphere of the brain that is processed, the lateral ventricle and the basal ganglia must be manually filled. The fornix, the optic nerve and usually the cerebellum were also removed by the user, a somewhat tedious task. Generally the cerebellum is not removed by automated processing and must be performed by manual editing, just as the fornix and optic nerve were. The reason for these deletions and fillings is to create a surface that is more easily processed by the automated methods that follow, including topological correction. These modifications to the surfaces are rather minor, but have pay off in the form of faster processing that follows. FreeSurfer uses a topology fixer which automatically removes most, if not all, handles or holes after completion of manual edits in the surface. FreeSurfer renders topologically correct WM and GM surfaces.

A novel approach to validating these surfaces revolves around measuring the length of the dominant sulci that are a result of consistent gyrfication across subjects, such as the central sulcus. These sulcal distances are measured with in-house software TopoCV[5], and are compared with published values[6]. The vertex points of sulci on the surface can be considered paths of negative mean curvature. These paths are created dynamically by selecting end point vertices from which sulcal length is calculated. Volumetric analysis of the GM and the cerebral WM are also provided by BrainVISA and FreeSurfer. Surface areas of the surface reconstructions were calculated using TopoCV.

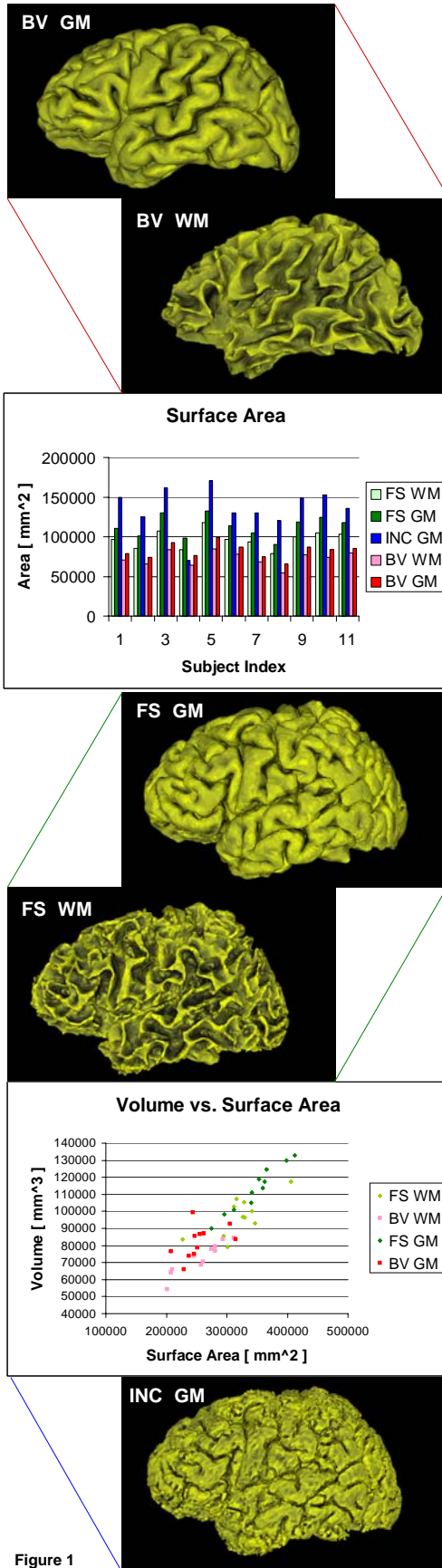


Figure 1

Surface images are from the same subject and exemplify texture and shape differences between methods. On average, INCsurf (INC) creates the largest surface areas and volumes, followed by FreeSurfer (FS), and then BrainVISA (BV).

Results

Central Sulcus length: The central sulcus lengths were measured on the WM surfaces that were rendered by FreeSurfer and BrainVISA so values could be compared with summary anatomical autopsy data (n=25)[6]. The lengths of the central sulcus on FreeSurfer and BrainVISA WM surfaces were statistically significantly different (p<0.01) as determined by the Wilcoxon matched pairs signed rank test. Since INCsurf does not make a WM surface, no central sulcus measurements are reported for INCsurf.

WM Central Sulcus Lengths			
	FreeSurfer	BrainVISA	Autopsy [6]
Avg length	130 mm	94 mm	94 mm
(range)	(113, 162)	(80, 104)	(70, 125)

Volume: The FreeSurfer WM mean volume of 320,693 mm³ was significantly larger than the BrainVISA WM mean volume of 254,967 mm³ (2 sample t-test, n=11, p=0.001). Likewise, the mean FreeSurfer GM volume of 346,727 mm³ was larger than the mean BrainVISA GM volume of 254,459 mm³ (2 sample test, n=11, p<0.001). The mean GM/WM ratios for FreeSurfer and BrainVISA were 1.089 and 1.002 respectively. INCsurf in-house volume calculations were abnormally large, necessitating further investigation.

Surface Area: The mean WM surface area of 97,063 mm² for the FreeSurfer method was larger than the mean BrainVISA WM surface area of 72,689 mm² (2 sample t-test, n=11, p<0.001). The FreeSurfer mean GM surface area 112,934 mm² was larger than the BrainVISA GM surface area mean of 82,214 mm² (2 sample t-test, n=11, p<0.001). The INCsurf GM surface area was large in comparison to the other two methods for most subjects. Likely contributing factors to this increased surface area are "spikes" on the GM surface, as opposed to a smooth surface.

Conclusions

FreeSurfer and BrainVISA tend to have the most consistent values in the 3 attributes we examined though FreeSurfer tends to have a larger brain rendering as indicated by WM central sulcus length, WM and GM volumes, and WM and GM surface areas. INCsurf is probably not the best choice for cortical surface reconstruction due to large volume and surface area characteristics. BrainVISA is the most automated of the 3 methods and appears to be more accurate when creating sulcal lengths on the WM surface as confirmed by anatomical values. We also found that about 25% of the surfaces produced by FreeSurfer had topology problems and needed to be further processed with TopoCV for topology correction. Brain images in Figure 1 exemplify significant variability in the shape of WM surfaces between methods, while the GM surfaces are more consistent in their gyrfication. Difficulty in evaluation stems from the unique brain shape of each subject. Further investigation may include the comparison of surface reconstructions from MRI data with anatomical autopsy measurements for the same subjects.

References

- [1] Stern, J. et al. Automatic surface extraction by discrete, topologically-controlled, region growing. *NeuroImage*. 13, S44 (2001).
- [2] Mangin, J. F. et al. Object-based morphometry of the cerebral cortex. *IEEE Trans. Med. Imaging*. 23(8), 968-982 (2004). <http://brainvisa.info/>
- [3] Dale, A. M. et al. Cortical surface-based analysis: I. segmentation and surface reconstruction. *NeuroImage*. 9, 179-194 (1999). <http://surfer.nmr.mgh.harvard.edu/>
- [4] LaConte, S. et al. The evaluation of preprocessing choices in single-subject BOLD fMRI using NPAIRS performance metrics. *NeuroImage*. 18, 10-27 (2003).
- [5] Hurdal, M. K. and Stephenson, K. Cortical cartography using the discrete conformal approach of circle packings. *NeuroImage*. 23, S119-S128 (2004).
- [6] Ono, M. et al. Atlas of the cerebral sulci. 1990.

Acknowledgements

This work is supported in part by NSF grant DMS-0101329 and NIH Human Brain Project grant P20 EB02013, a FSU Howard Hughes Medical Institute Fellowship in Computational and Mathematical Biology and a FSU Bess Ward Travel Fellowship. We would like to thank Dr. David Rottenberg, Departments of Radiology and Neurology, University of Minnesota for providing the MRI data, in addition to Daniel Hernandez and Robert Harris for assistance with the images and sulcus tracing.

For more information, contact
Aaron D. Kline: Email: akline@math.fsu.edu or
Dr. Monica K. Hurdal: Email: mhurdal@math.fsu.edu,
URL: <http://www.math.fsu.edu/~mhurdal>